

# Evaluating the Quality of Rigid Optic Videolaryngoscopy Image Taken Through Dental Protection Cap and Its Feasibility as Additional Barrier Method Against COVID-19

\*Mariana Nagata Cavalheiro, \*†‡§Vinicius Ribas Fonseca, ‡Bianca Simone Zeigelboim, \*Diego F. Costa, \*Lucas Viomar de Lima, ||Marlon Kleber Bozzo, ||Rita de Cássia Tonochi, and \*Bruno Ceron Hartmann, \*, †, ‡, §Brazil, and ||

**Summary:** Videolaryngoscopy screening is essential to help assessing human larynx. The use of 70° optical fiber in association with image recording by analog or digital cameras is one of the methods adopted to perform this examination. Endoscopic exams can contaminate the equipment with several microorganisms. The pandemic caused by the new coronavirus reinforces the importance of developing efficient barrier methods to be adopted in videolaryngoscopy procedures. Although dental intraoral camera covers are a barrier method authorized by Brazilian health organs, it has not yet been used in videolaryngoscopy examinations. The aim of the current longitudinal, individualized, single-blind, prospective, self-controlled, and accurate study is to evaluate the quality of images generated through, and confidence level of, diagnosis based on videolaryngoscopy performed with intraoral dental camera equipped with disposable protection cap and connected to 70° rigid laryngoscope in vocally healthy individuals. Videolaryngoscopy examinations based on 70° rigid optics were performed in 13 euphonic and asymptomatic volunteers at an otorhinolaryngology specialist clinic; only 1 patient was excluded from the study. Images were taken with, and without, disposable intraoral dental camera protection cap; high-grade disinfection protocol was applied between examinations. Recorded videos were randomly distributed in a single-blind manner in order to be evaluated by four otorhinolaryngologists, who answered a questionnaire comprising three questions. Statistical analysis was used to compare groups – which were defined by the use, or not, of protection cap – based on Wilcoxon nonparametric test. Statistical significance was set at 5% with 95% confidence interval. There was no statistically significant difference in image quality between examinations performed with, and without, protection cap ( $P= 0.646$ ) or in the diagnosis confidence level of examinations performed with, or without, the barrier method. The use of disposable protection cap on intraoral dental camera did not significantly change the quality of images taken through videolaryngoscopy performed with 70° rigid optics in vocally healthy patients.

**Key Words:** Coronavirus–COVID-19–Protection–Barrier–Laryngoscopy–Dental–Image.

## INTRODUCTION

Larynx visualization through different methods is an essential practice in the Otorhinolaryngology (ENT – ear, nose, throat) field; it is described as the crucial step to enable the diagnosis of pathologies in this segment.<sup>1</sup> Since the 19th century, when Garcia's mirror for indirect larynx inspection was first used, methods have significantly advanced, mainly after 1970, due to the introduction of the optical fiber technology.<sup>2–4</sup>

The 70° and 90° rigid fiberoptic laryngoscopes stand out among several methods available nowadays. According to Shao et al, the 70° rigid fiberoptic laryngoscope is the most used method for laryngeal examination.<sup>3</sup> Assumably, flexible laryngoscopes are better tolerated by patients with intense nauseated reflexes, as well as with cervical

movement and mandibular opening limitation, and they are even preferred by some authors.<sup>3–5</sup> The technological advancement enabled developing rigid laryngoscopes equipped with camera and chip attached to its tip, a fact that made it possible digitizing images taken during the examinations. Therefore, these devices stand out for generating high-quality images during the examinations.<sup>6</sup> Plaat et al have demonstrated that images generated by such devices are significantly better than the ones generated by conventional fiber optic laryngoscopes, and this finding is in compliance with the literature.<sup>1,4</sup>

Endoscopes used in these imaging methods are often contaminated with a range of microorganisms as they pass through the mucosa of the upper airways. Thus, it is mandatory performing efficient decontamination procedures to avoid the risk of cross-contamination between patients subjected to this examination, and between patients and examiners, vice versa.<sup>4,5,7–11</sup>

The severe acute respiratory syndrome caused by the new coronavirus (SARS-CoV-2) emerged in Wuhan (China), in December 2019; it presented high dissemination potential and rapid increase in the number of confirmed cases in other countries.<sup>12–14</sup> Clinical features of the disease caused by SARS-CoV-2 (COVID-19) – such as cough, body

Accepted for publication October 20, 2020.

From the \*Lauro Grein Filho Center for Otorhinolaryngological Studies; †Positivo University; ‡Postgraduate Program in Communication Disorders, Tuiuti do Paraná University; §Brazilian Red Cross Hospital, Paraná, Brazil; and the ||Communication Disorders at Tuiuti do Paraná University.

Address correspondence and reprint requests to Bruno Ceron Hartmann, Rua Marquês do Paraná, 1275, Apartamento 43, Bloco A, bairro Água Verde, Curitiba, Paraná CEP: 80620-210, Brazil. E-mail: hartmannbc@gmail.com

Journal of Voice, Vol. 37, No. 1, pp. 141.e13–141.e21  
0892-1997

© 2020 The Voice Foundation. Published by Elsevier Inc. All rights reserved.  
<https://doi.org/10.1016/j.jvoice.2020.10.014>

temperature (fever) higher than 38°C, headache, sore throat, nasal obstruction, olfactory loss, asthenia, rhinorrhea, myalgia, and taste disorders – have been progressively elucidated in multicenter studies conducted worldwide.<sup>12–16</sup> However, effective antiviral drugs capable of treating the SARS-CoV-2 are not yet available.

Accordingly, multicenter studies have shown that otorhinolaryngologists, ophthalmologists, anesthesiologists, and intensive care physicians are the medical professionals mostly infected by COVID-19 in Asia, Europe, and in the United States.<sup>17–21</sup> These professionals are often in close contact with patients' oral and nasal cavities; thus, they are susceptible to the high potential of viral dissemination through secretions found in these cavities.<sup>17,18</sup> Still, procedures associated with these specialties – such as orotracheal intubation – as well as procedures involving patients' respiratory and gastrointestinal tracts, such as endoscopy, bronchoscopy, and laryngoscopy, present high aerosolization risk.<sup>17</sup>

Thus, it is valid reinforcing the use of barrier methods in otorhinolaryngological equipment. According to Spaulding's classification - used in the CDC's 2008 disinfection and sterilization guide for health facilities - objects that have contact with mucous membranes and oral fluids are categorized as semicritical; thus, they require proper cleaning and, at least, high level disinfection after each use.<sup>9</sup> It is worth emphasizing that this statement is consistent with guidelines released by the main Brazilian national body (ANVISA - 2006, 2009, and 2012) associated with this subject.

According to a Brazilian decree from 2012, the processing of health products must follow a Standard Operational Protocol (SOP) based on updated scientific references and on pertinent regulations. In this very same year, the Brazilian Association of Otorhinolaryngology and Cervical-Facial Surgery (ABORL-CCF – Associação Brasileira de Otorrinolaringologia e Cirurgia Cérvico-Facial) developed an SOP to process materials used in nasoendoscopy, videolarngoscopy (VL), and videonaso-pharyngo-laryngoscopy examinations in medical practices. This SOP enabled eliminating 99.9415% of organic material by cleaning and disinfecting the used devices with 70% alcohol, for approximately 15 minutes. However, some manufacturers have their own protocols, which add a step to the protocol: liquid asepsis based on the immersion of the optics (only) in 0.2% peracetic acid solution for 2 minutes,<sup>8,9,11</sup> among others.

The intraoral dental camera protection cap is a disposable device used by dentists to perform exams in the oral cavity; however, it was first used as protection cap for videolarngoscopes by Fonseca et al.<sup>22</sup> This device is made available by several brands in the market; it has clearance by health surveillance agencies, since its effectiveness as barrier method has been confirmed. In addition, it is easily found in low-cost dental material houses, where unit prices range from R\$ 0.25 to R\$ 1.00, depending on the brand and on place of purchase.

The aim of the current study was to evaluate the quality of images generated through, and the confidence level of

diagnosis based on VL examinations performed with intraoral dental camera equipped with disposable protection cap and connected to 70° rigid laryngoscope in vocally healthy individuals, we all as the feasibility of using it in the current pandemic context of COVID-19.

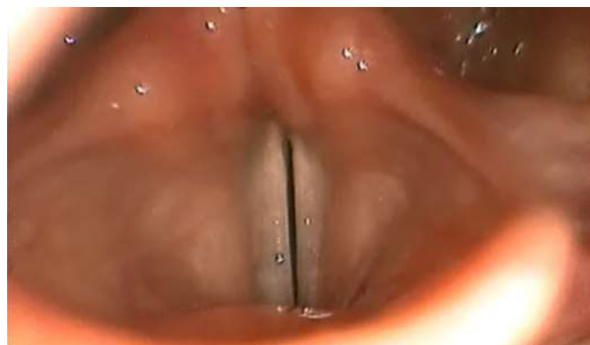## METHOD

Data collection was carried out after the study was approved by the ethics committee on human research, under opinion no. 1.761.602.

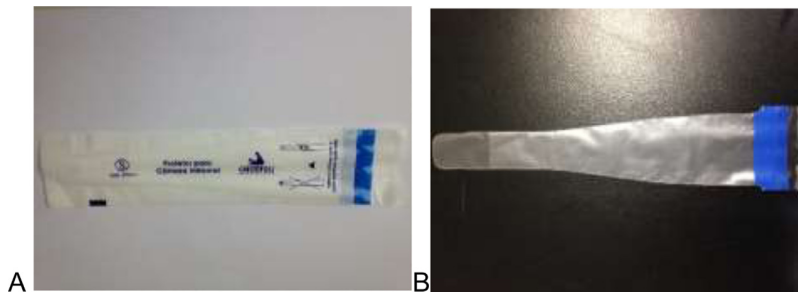
Twenty-six (26) examinations were performed (13 with, and 13 without, the dental protection cap [DPC]) in 13 euphonic and asymptomatic volunteers. Each volunteer underwent the examination with, and without, the intraoral protection cap. All participants signed the informed consent form. Inclusion criteria comprised willingness to participate in the study and not having history of previous laryngeal surgery or current laryngeal pathology under treatment. Exclusion criteria encompassed intense nauseated reflex, anatomy impairing the quality of the exam, and presenting dysphonia or laryngeal pathologies capable of hindering the diagnosis. One (1) of the 13 volunteers has shown vocal fold immobility and was excluded from the study; thus, the final sample comprised 12 volunteers and totaled 24 examinations.

## Image generation

Images were generated through traditional VL ([Image 1](#)) equipped with 70° Shen rigid optics made in China and coupled to Doctus Led Light source and Ecleris camera (Procam SC model) made in Argentina. Images were captured during inspiration and phonation, and visualized at the basis of the epiglottis, as well as in both arytenoids, posterior commissure and both ventricular bands to enable better larynx assessment. Efforts were made to assure that the quality of the generated images was not impaired by preventable causes such as bubbles, fogging, or lack of focus. Examinations were carried out in ENT clinic, by a single ENT doctor, under the same camera adjustment, focus, and brightness conditions.



**IMAGE 1.** Traditional videolarngoscopy with 70° rigid optics.



**IMAGE 2.** Cristófoli Biosafety intraoral camera protection cap A inside the sterile protective wrapper and B outside the wrapper.

Images were captured at two different stages. The first stage used the intraoral camera protection cap (**Image 2**). The laryngoscope equipment was wrapped in Cristófoli Biosegurança protection cap (ANVISA Registration no. 10363359004, Cristófoli Equipamentos de Biossegurança LTDA., Campo Mourão, Brazil) before the VL examination was performed. As for the second stage, the intraoral protection cap was removed and the examination was carried out with the same equipment. Images generated in both stages were captured in Samsung DVD recorder. After images were generated with, and without, the barrier protection method, the equipment was subjected to cleaning and disinfection procedures, based on the SOP by ABORL, before it was used in the following volunteer.

Recorded videos were edited in Windows Movie Maker software (Microsoft Corporation, Redmond) in order to form 10-second clips. After the editing procedure was over, clips were distributed and randomized in Microsoft Excel 2013 (Microsoft Corporation, Redmond). Participants' personal information was removed. Randomized images were

randomly presented – in a single-blind manner, at different times – to four experts in VL evaluation, who answered a three-question questionnaire (**Chart 1**). Images – without additional information about participants' history, besides the ones available in the questionnaire – were shown to each examiner, in an independent manner, for 10 seconds, using Microsoft PowerPoint 2013 (Microsoft Corporation, Redmond) in a Samsung RV411 laptop equipped with color LCD screen. After evaluating each exam, examiners answered the three questions in order to individualize the answers per examination. After the questionnaire application was over, data were tabulated in Microsoft Excel 2013 software to statistical analysis.

### Statistical analysis

Mean, median, minimum, and maximum values, first and third quartiles, and standard deviation were used to describe the analyzed data. These parameters were also used to compare exams performed with, and without, intraoral

#### CHART 1.

##### Questionnaire Applied to Image Evaluation With, and Without, Intraoral Protection Cap

1) How do you classify the quality of the image in the exam?	<b>1. Extremely poor</b> <b>2. Poor</b> <b>3. Moderate</b> <b>4. Good</b> <b>5. Excellent</b>
2) By taking into consideration that the patient is euphonic and asymptomatic, can you diagnose this exam as normal or abnormal? And if abnormal, what is the abnormality in it?	<b>1. Normal</b>  <b>2. Abnormal:</b> <b>Classify from 1 to 10, as follows:</b>
3) How would you rate the confidence level of the diagnosis? (by taking into account the quality of the image to make your diagnosis)	<b>1. No confidence at all</b> <b>10. Fully safe.</b>

1. Extremely poor: is not possible evaluate the exam; 2. Poor: is possible evaluate the exam but is difficult to see the structures; 3. Moderate: is possible evaluate the exam but some details can not be seen; 4. Good: is possible evaluate the exam without any problem; 5. Excellent: a perfect image that exam can provide us.

1. Normal: according to normality criteria; 2. Abnormal: disaccording to normality criteria; Classify from 1 to 10, as follows: choose one of the filling options.

protection cap. Wilcoxon's nonparametric test was used to evaluate questionnaire responses. Spearman's correlation coefficients were estimated to assess the association between quality of image and confidence level of diagnosis;  $P < 0.05$  has indicated statistical significance. Data were analyzed in the IBM SPSS Statistics v.20.0 software (Armonk, NY: IBM Corp.).

## RESULTS

### Sample analysis

Twenty-six (26) examinations were performed in 13 volunteers (13 with, and 13 without, DPC); however, 1 volunteer was excluded because he presented vocal fold immobility in median position. Exclusion criteria application resulted in 24 examinations performed in 12 volunteers – 3 men and 9 women.

### Evaluating the formulated questions

*Question 1: How do you classify the quality of the image? (Based on a 1–5 scale)*

We tested the null hypothesis of equal image quality-assessment scores for with-cap and without-cap assessments versus the alternative hypothesis of different scores. The table below shows the descriptive statistics applied to each group (with, and without, cap), as well as to score differences (without cap minus with cap). This table also shows the  $p$  value in the statistical test. Based on statistical analysis results, there was not statistically significant difference between the quality of images generated with, or without, the protection cap;  $P$  value was .646.

*Question 2: Can you make a diagnosis? (Yes or no)*

The percentage of normal results recorded for each exam was calculated as the ratio between the number of results classified as normal by all four examiners divided by the number of examiners.<sup>4</sup> There was not statistically significant difference between the percentage of results classified as normal by examiners in exams conducted with protection cap and the percentage of results classified as normal in exams conducted without it ( $P = .424$ ).

*Question 3: How do you rate the confidence level of the diagnosis? (Based on a 1–10 scale)*

We tested the null hypothesis that scores recorded for the confidence level of the diagnosis were equal in assessments with, and without, protection cap versus the alternative hypothesis of different scores. Table 3 shows the descriptive statistics applied to each group (with, and without, protection cap), as well as to score differences (without cap minus with cap). This table also shows the  $dep$  value of the statistical test, which reached 0.638, ie, there was not statistically significant difference in the confidence level between exams conducted with, and without, DPC.

### Evaluating the association between image quality and confidence level of diagnosis

Spearman's correlation coefficient was estimated in each cap-defined group (without and with) in order to assess the association between image quality and confidence level of the diagnosis.

Thus, we tested the null hypothesis of Spearman's correlation coefficient equal to zero (no association) versus the alternative hypothesis of nonzero Spearman's correlation coefficient (existence of association). Chart 2 below presents the results recorded in the study (estimated correlations and  $dep$  values of statistical tests). They indicate positive association between image quality and confidence level of the diagnosis for exams conducted with, and without, DPC – ie, the higher the quality of the image, the higher the confidence level of the diagnosis, based on examiners' assessment.

## DISCUSSION

We observed the progressive need of intensifying the use of barrier methods in ENT procedures throughout 2020, due to the pandemic caused by the SARS-CoV-2. The need of performing exams with potential to produce aerosols under these conditions certainly requires changes in usual practices to avoid spreading the disease among patients and health professionals.<sup>23,24</sup>

The use of barrier devices, such as disposable caps, is addressed as optional by the previously mentioned CDC (2008) guidelines, as well as by the 2003 guideline for infection control in dental health by the same agency.<sup>9,11</sup> There are reports about the use of disposable caps as barrier method in otorhinolaryngological exams since 1993,<sup>25</sup> as well as in other endoscopic exams such as sigmoidoscopy.<sup>26</sup> Several studies have shown the value of disposable caps for the quality of image, as well as their applicability and effectiveness as barrier mechanism.<sup>1,4,7,8,10,25,27–29</sup> One of them (conducted in 2014) showed that the use of the Slide-On EndoSheath System cap (Medtronic Xomed Inc) decreased the quality of the image generated during VL conducted with endoscope equipped with distal chip camera, although it did not affect the confidence level of the diagnosis.<sup>1</sup> Nevertheless, Silberman has evaluated the use of a disposable cap similar to the Slide-On EndoSheath one and found that, besides maintaining the quality parameters of the video naso-pharyngo-laryngoscopy exam, the cap enabled gaining time between examinations due to its easy and quick use and to lack of need to adopt traditional cleaning and disinfection methods. The aforementioned author addressed the use of the protection cap as a viable option for otorhinolaryngologists.<sup>10</sup>

The use of disposable caps in endoscopic exams conducted in the Otorhinolaryngology field remains a controversial topic in the literature, but the possibility of using them is a subject of great value in the current health scenario imposed by COVID-19. Some studies have stated that using the cap is safe because it helps preventing cross-contamination by microorganisms,<sup>28,29</sup> whereas others advocated that

it is not recommended giving up on performing high-level endoscope disinfection between patients, despite the use of such a device.<sup>7,8</sup> Conflicting results about changes in the quality of image were also observed in different studies that have used disposable barrier devices in endoscopic exams conducted in the Otorhinolaryngology field.<sup>1,4,10,25,26</sup>

We opted for using the intraoral dental cap as barrier method in the current study due to its greater availability in the national market, as well as to its low cost in comparison to caps currently available in the national and international markets. In addition, the use of the cap requires shorter time than the disinfection process suggested in the SOP by ABORL, which is not universally accepted by the national epidemiological and sanitary surveillance departments or even by ANVISA. Another aspect to be taken into consideration is that the disinfection with peracetic acid solution suggested by ANVISA can damage the optics used in the examinations.<sup>10</sup>

Based on results in the current study, there was not statistically significant difference in the quality of images between examinations conducted with, and without, the tested protection cap (Question 1). This finding was not in compliance with some findings available in the literature, since two studies conducted by Plaat et al<sup>1,4</sup> observed that the use of disposable cap in laryngoscopy examinations. Unlike the current study, which used a rigid endoscope, Plaat et al used an endoscope with distal chip camera, which reduced the quality of the generated image ( $P < 0.05$ ). However, according to the aforementioned authors, there was not statistically significant difference in the confidence to diagnose the exam or in the diagnostic accuracy. In addition, Vaz et al<sup>18</sup> were also adamant in stating that using such a device changes the quality of the image. On the other hand, Silberman has stated that the use of disposable cap in flexible nasofibrolaryngoscopy examinations did not influence the quality of the generated image.<sup>10</sup>

Assumingly, the use of intraoral DPC has led to better image quality results in the current study than the ones recorded in other studies; it happened because the DPC is easier to use, more transparent and presents design better adapted to optics than devices used in other studies available in the literature. This hypothesis requires performing direct comparative study between caps in order to be ultimately confirmed; however, this comparison transcends the scope of the present study.

According to the present study, the better the quality of image, the greater the confidence in diagnosing the exam. Based on analysis of the possibility of making a diagnosis and of the confidence in the image generated for that purpose (Questions 2 and 3, respectively), there was also not statistically significant difference between exams conducted with, and without, the disposable cap ( $P > 0.05$ ). These data were consistent with results found in the literature<sup>1,4</sup>; thus, it is possible stating that the use of disposable cap in the current study did not change the quality of the image of the exam to the point of generating statistically significant difference between diagnostic outcomes with, and without, such a device.

With respect to disagreements in the current study about the quality of image in exams conducted with intraoral camera protective cap and protective caps used in laryngoscopy examinations, studies comprising larger samples may show whether the quality of the image of the intraoral protection cap is better than that of the laryngoscopy protection cap in traditional rigid endoscopes.

Cai and collaborators<sup>23</sup> have report changes in ENT procedures' routine in the United States due to the SARS-CoV-2 pandemic scenario, such as avoiding nasal sprays before nasal endoscopy procedures, prioritizing the use of small topical anesthetic compress, generating lesser sneeze reflex and subsequent droplet aerosolization. In addition, laryngoscopy exams must be performed by experts in order to better handle patients' airways.<sup>23</sup> However, the literature lacks studies about the options of equipment to be used.

During the COVID-19 pandemic, most national and international Otorhinolaryngology and Cervical-Facial Surgery societies tend to consider laryngoscopy as strictly necessary only in critical cases, since its performance has direct impact on patients' management<sup>24,30</sup>; however, it is mandatory performing the efficient screening of possible infected individuals, using PPE and maintaining distance from patients in all steps before the procedure.<sup>24,30</sup> On the other hand, the literature lacks proposals to optimize the use of this equipment, by maintaining reprocessing with isopropyl alcohol and glutaraldehyde,<sup>24,30</sup> which have strong potential to damage the integrity of telescopes currently used for laryngoscopy purposes. This conflicting scenario reinforces the importance of conducting research about the use of protection caps and barrier methods, such as the herein conducted one. Additional studies on the use of protection caps in laryngoscopes can help better understanding the effectiveness of this method (Chart 2).

Although disposable caps are not recently developed devices,<sup>16</sup> they require solid proof about their benefit and safety of use; however, it is plausible saying that they are promising devices for the advancement in endoscopic imaging screening in the Otorhinolaryngology field (Tables 1, 2).

The current team of researchers has other studies in progress in order to prove the effectiveness of intraoral camera protection caps as barrier method against the contamination of VL equipment by microorganisms, as well as to evaluate the quality of VL images generated in other devices, such as laryngoscopes equipped with distal chip camera, by using protection caps (Image 3).

**CHART 2.**  
**Results of Confidence Level Evaluation in the Diagnosis of Examinations Conducted With, and Without, Dental Protection Cap.**

	Spearman's Correlation Coefficient	P Value
Without	0.74	0.006
With	0.67	0.016

**TABLE 1.**  
**Image Quality-Evaluation Results of Participants Examined With, and Without, Protection Cap**

Cap	n	Mean	Min. Value	First Quartile	Median	Third Quartile	Max. Value	Stand. Dev.	<i>P</i> * Value
With	12	3.3	1.8	3.2	3.5	3.8	4.0	0.6	
Without	12	3.3	2.5	3.2	3.3	3.6	3.8	0.4	
Dif. (without – with)	12	0.0	-1.5	-0.4	0.0	0.5	1.5	0.7	0.646

\* Wilcoxon’s nonparametric test; *P* < 0.05.

**TABLE 2.**  
**Results of the Evaluation of Exams Classified as Normal or Abnormal With, and Without, Dental Protection Cap**

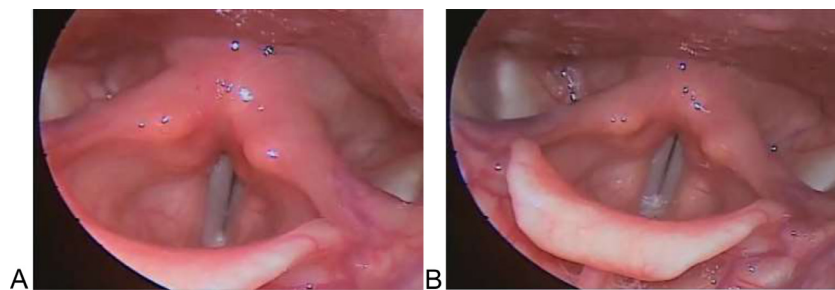
Cap	n	Mean	Min. Value	First Quartile	Median	Third Quartile	Max. Value	Stand.Dev.	<i>P</i> * Value
Without	12	50.0%	0.0%	25.0%	37.5%	75.0%	100.0%	33.7%	
With	12	60.4%	0.0%	43.8%	75.0%	75.0%	100.0%	31.0%	
Dif. (without – with)	12	-10.4%	-75.0%	-50.0%	-12.5%	25.0%	50.0%	45.8%	0.424

\* Wilcoxon’s nonparametric test; *P* < 0.05.

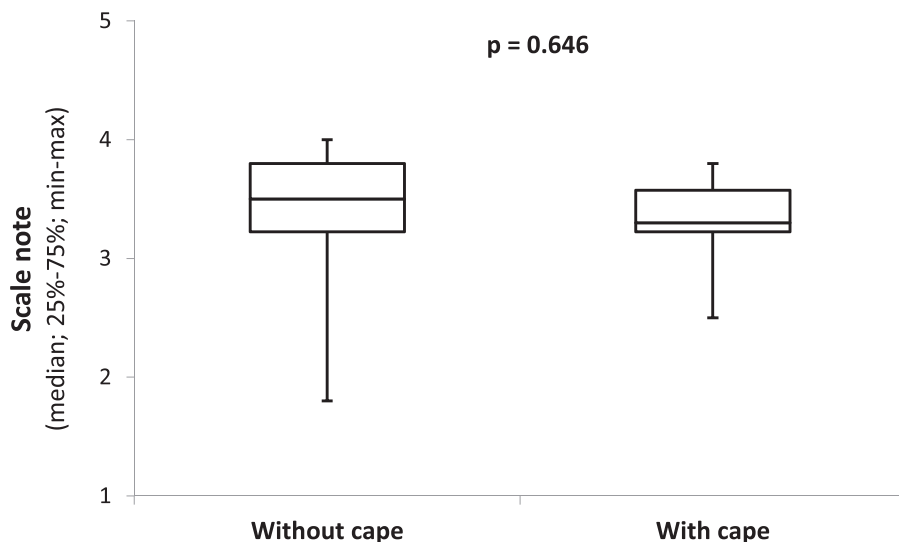
**TABLE 3.**  
**Result of the Evaluation of the Confidence Level in the Diagnosis of Exams Conducted With, and Without, Dental Protection Cap**

Cap	n	Mean	Min. Value	First Quartile	Median	Third Quartile	Max. Value	Stand. Dev.	<i>P</i> * Value
Without	12	6.1	2.0	5.4	6.6	7.1	7.8	1.7	
With	12	6.4	4.0	6.0	6.7	7.0	8.3	1.1	
Dif. (without – with)	12	-0.4	-3.8	-1.6	0.3	0.8	3.5	2.0	0.638

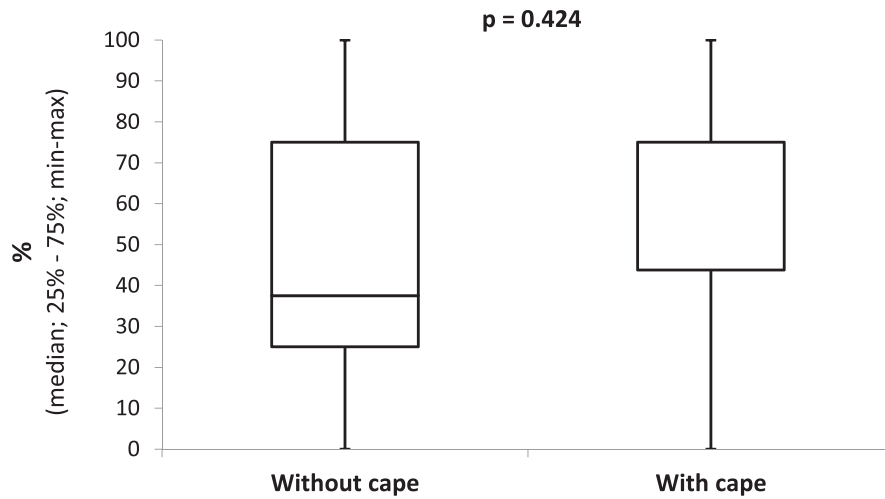
\* Wilcoxon’s nonparametric test; *P* < 0.05.



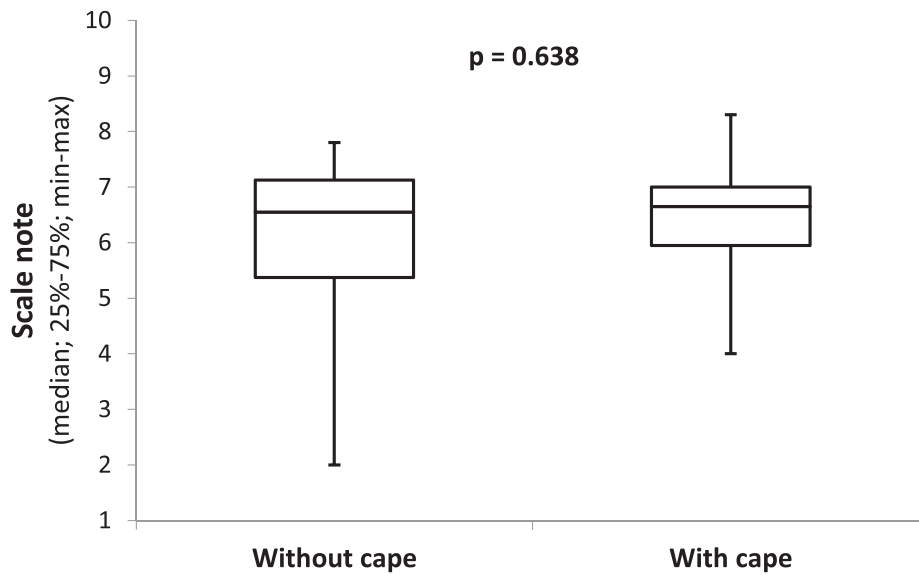
**IMAGE 3.** Images showing the same larynx: (A) without dental protection cap (DPC) and (B) with DPC.



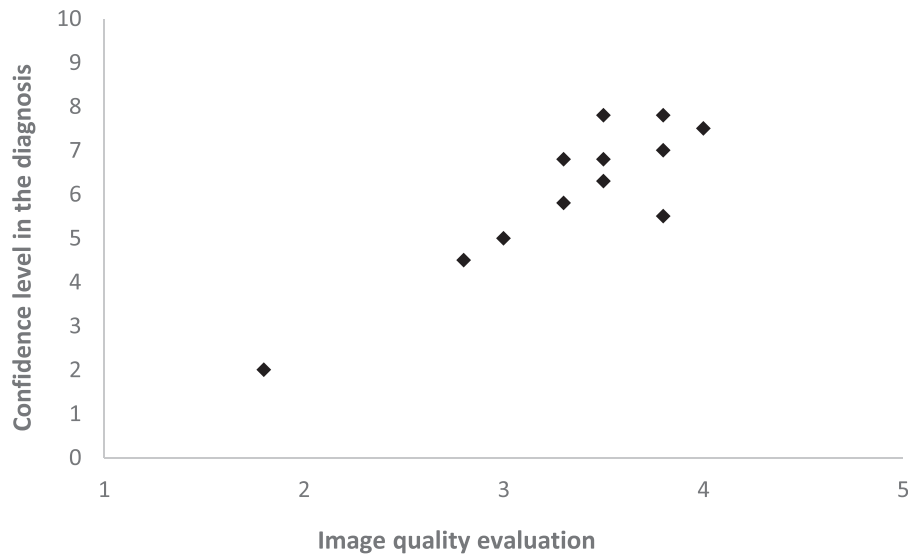
**GRAPH 1.** Quality of the exam with, and without, dental protection cap.



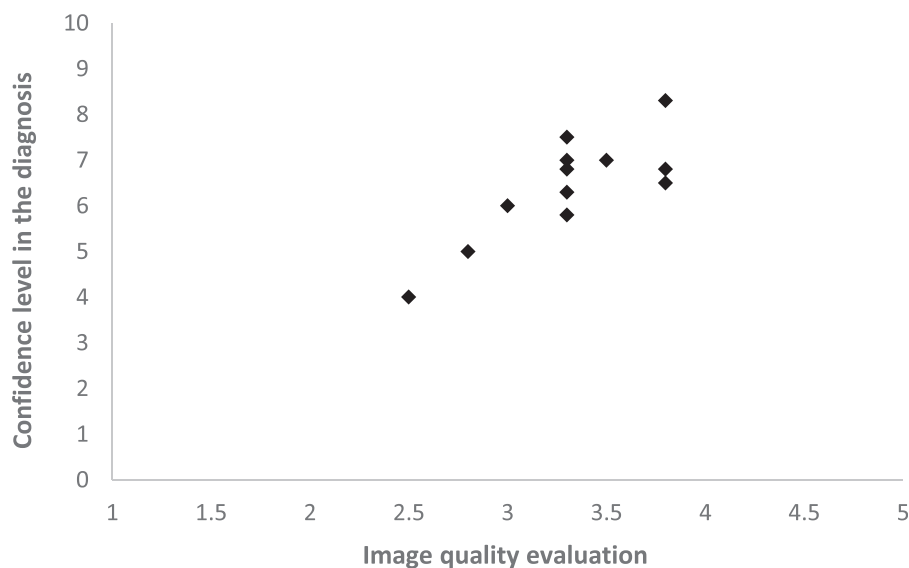
**GRAPH 2.** Examiners' likelihood of diagnosing the exams as normal or abnormal.



**GRAPH 3.** Confidence level in the diagnosis of exams conducted with, and without, dental protection cap.



**GRAPH 4.** Confidence level in the diagnosis of examinations conducted without dental protection cap.



**GRAPH 5.** Confidence level in diagnosis of examinations conducted with dental protection cap.

### CONCLUSION

The use of dental intraoral camera cap did not significantly change the quality of image and the confidence in the diagnosis of VL examinations conducted with 70° rigid optics in vocally healthy individuals (Fig. Graph 1, Graph 2, Graph 3, Graphs 4 and Graph 5).

### SUPPLEMENTARY DATA

Supplementary data related to this article can be found online at [doi:10.1016/j.jvoice.2020.10.014](https://doi.org/10.1016/j.jvoice.2020.10.014).

### REFERENCES

1. Plaat BEC, van der Laan BFAM, Wedman J, et al. The effect of endoscopic sheaths on visualization in distal chip and fiberoptic laryngoscopy. *Eur Arch Otorhinolaryngol*. 2014;271:2757–2760.
2. Feder R. On standardizing the laryngeal examination. *Arch Otolaryngol – Head Neck Surg*. 1986;112:145.
3. Shao J, Stern J, Wang Z-M, et al. Clinical evaluation of 70° and 90° laryngeal telescopes. *Arch Otolaryngol – Head Neck Surg [Internet]*. 2002;128:941–944.
4. Plaat BEC, Van Der Laan BFAM, Wedman J, et al. Distal chip versus fiberoptic laryngoscopy using endoscopic sheaths: diagnostic accuracy and image quality. *Eur Arch Oto-Rhino-Laryngol*. 2014;271:2227–2232.
5. Collins WO. A review of reprocessing techniques of flexible nasopharyngoscopes. *Otolaryngol - Head Neck Surg [Internet]*. Elsevier Inc.. 2009;141:307–310.
6. Kawaida M, Fukuda H, Kohno N. Digital image processing of laryngeal lesions by electronic videoendoscopy. *Laryngoscope [Internet]*. 2002;112(3):559–564.
7. Baker KH, Chaput MP, Clavet CR, et al. Evaluation of endoscope sheaths as viral barriers. *Laryngoscope*. 1999;109:636–639.
8. Muscarella LF. Prevention of disease transmission during flexible laryngoscopy. *Am J Infect Control*. 2007;536–544.
9. Rutala WA, Weber DJ, HICPAC. Guideline for disinfection and sterilization in healthcare facilities. *Dept Health Human Serv – CDC*. 2008:1–158.
10. Silberman HD. Non-inflatable sterile sheath for introduction of the flexible nasopharyngolaryngoscope. *Ann Otol Rhinol Laryngol*. 2001;110:385–387.
11. Collins AS, Cleveland JL, Harte JA. Guidelines for infection control in dental health-care settings – 2003. *Prepared Guidel Infect Control Dent Heal Settings*. 2003;52(52(RR17):1–61.
12. Huang R, Zhu L, Xue L, et al. Clinical findings of patients with coronavirus disease 2019 in Jiangsu province, China: a retrospective, multi-center study. *PLoS Negl Trop Dis*. 2020;14: e0008280. <https://doi.org/10.1371/journal.pntd.0008280>.
13. Lechien JR, Chiesa–Estomba CM, Place S, et al. Clinical and epidemiological characteristics of 1,420 European patients with mild–to–moderate coronavirus disease 2019. *J Int Med*. 2020. <https://doi.org/10.1111/joim.13089>.
14. Tong JY, Wong A, Zhu D, et al. The prevalence of olfactory and gustatory dysfunction in COVID-19 patients: a systematic review and meta-analysis. *Otolaryngol Head Neck Surg*. 2020. <https://doi.org/10.1177/0194599820926473>. 0194599820926473.
15. Gold JA, Wong KK, Szablewski CM, et al. Characteristics and clinical outcomes of adult patients hospitalized with COVID-19 — Georgia, March 2020. *MMWR Morb Mortal Wkly Rep*. 2020;69:545–550. <https://doi.org/10.15585/mmwr.mm6918e1>.
16. Liu J, Chen T, Yang H, et al. Clinical and radiological changes of hospitalized patients with COVID-19 pneumonia from disease onset to acute exacerbation: a multicentre paired cohort study. *Eur Radiol*. 2020. <https://doi.org/10.1007/s00330-020-06916-4>.
17. Patel ZM, Fernandez-Miranda J, Hwang PH, et al. Letter: precautions for endoscopic transnasal skull base surgery during the COVID-19 pandemic. *Neurosurgery*. 2020. <https://doi.org/10.1093/neuros/nyaa125>.
18. Wang D, Hu B, Hu C, et al. Clinical characteristics of 138 hospitalized patients with 2019 novel coronavirus-infected pneumonia in Wuhan, China. *JAMA*. 2020. <https://doi.org/10.1001/jama.2020.1585>. Published online February 7.
19. McGoogan ZWJM. Characteristics of and important lessons from the coronavirus disease 2019 (COVID-19) outbreak in China. Summary of a report of 72 314 cases from the Chinese Center for Disease Control and Prevention. *Jama*. 2020. <https://doi.org/10.1001/jama.2020.2648>. Published Online: February 24.
20. 7ª Nota de orientação aos médicos Otorrinolaringologistas em relação à doença causada pelo novo Coronavírus (COVID-19) – Associação Brasileira de Otorrinolaringologia e Cirurgia Cérvico-Facial, 30 de março de 2020. Acessada em 12/05/2020 às 13:00 horas. Available at:



- [https://www.aborlccf.org.br/imageBank/-\\_2020-03-30\\_7%C2%AA\\_nota\\_aborl-ccf\\_abope\\_crianças\\_e\\_neonatos.pdf](https://www.aborlccf.org.br/imageBank/-_2020-03-30_7%C2%AA_nota_aborl-ccf_abope_crianças_e_neonatos.pdf).
21. Sadhu S, Agrawal R, Pyare R, et al. COVID-19: limiting the risks for eye care professionals. *Ocul ImmunolInflamm*. 2020. <https://doi.org/10.1080/09273948.2020.1755442>.
  22. Costa, D; Fonseca, VR; Bozo, M; et al. Analysis of videolaryngoscopy images with and without protective cover for the intraoral odontological camera. Anais do 47º Congresso da ABORL-CCF – 2017. Available at: <https://www.aborlccf.org.br/imageBank/ANAIS-DO-CONGRESSO-47CBO-2017-V4.PDF>.
  23. Cai Y, Jiam NT, Wai KC, et al. Otolaryngology resident practices and perceptions in the initial phase of the U.S. COVID –19 pandemic. *Laryngoscope*. 2020. <https://doi.org/10.1002/lary.28733>.
  24. Rameau A, Young VN, Amin MR, et al. *Flexible Laryngoscopy and COVID-19. Otolaryngology–Head and Neck Surgery*, 019459982092139. 2020. <https://doi.org/10.1177/0194599820921395>.
  25. Silberman HD, Hampel A, Kominsky AH. New technique for the sterile introduction of flexible nasopharyngolaryngoscopes. *Ann Otol Rhinol Laryngol*. 1993;102:687–689.
  26. Bretthauer M, Hoff G, Thiis-Evensen E, et al. Use of a disposable sheath system for flexible sigmoidoscopy in decentralized colorectal cancer screening. *Endoscopy*. 2002;34:814–818.
  27. Vaz F, Ripley L, Lim D, et al. Optical quality of the nasendoscope with and without the endosheath. *J Laryngol Otol*. 2006 May;120:385–388.
  28. Winter SC, Thirwell A, Jervis P. Flexiblenasendoscope with a disposable-sheath system versus standard nasendoscopy: a prospective, randomized trial. *Clin Otolaryngol Allied Sci*. 2002 Apr;27:81–83.
  29. Elackattu A, Zoccoli M, Spiegel JH, et al. A comparison of two methods for preventing cross-contamination when using flexible fiberoptic endoscopes in an otolaryngology clinic: disposable sterile sheaths versus immersion in germicidal liquid. *Laryngoscope*. 2010;120:2410–2416.
  30. De Luca P, Scarpa A, Ralli M, et al. Nasal, pharyngeal and laryngeal endoscopy procedures during COVID-19 pandemic: available recommendations from national and international societies. *Eur Arch Otorhinolaryngol*. 2020;277:2151–2153. <https://doi.org/10.1007/s00405-020-06028-1>. In press.